


# Grand Rounds



Motaseem Al-latayfeh, M.D.

University of Louisville

Department of Ophthalmology and Visual Sciences

10/1/10

# History

- CC:

33 yo female c/o reduced visual acuity in the right eye for 1 week.

- HPI:

- Known case of choroidal melanoma s/p plaque radiotherapy in Jan, 2009.

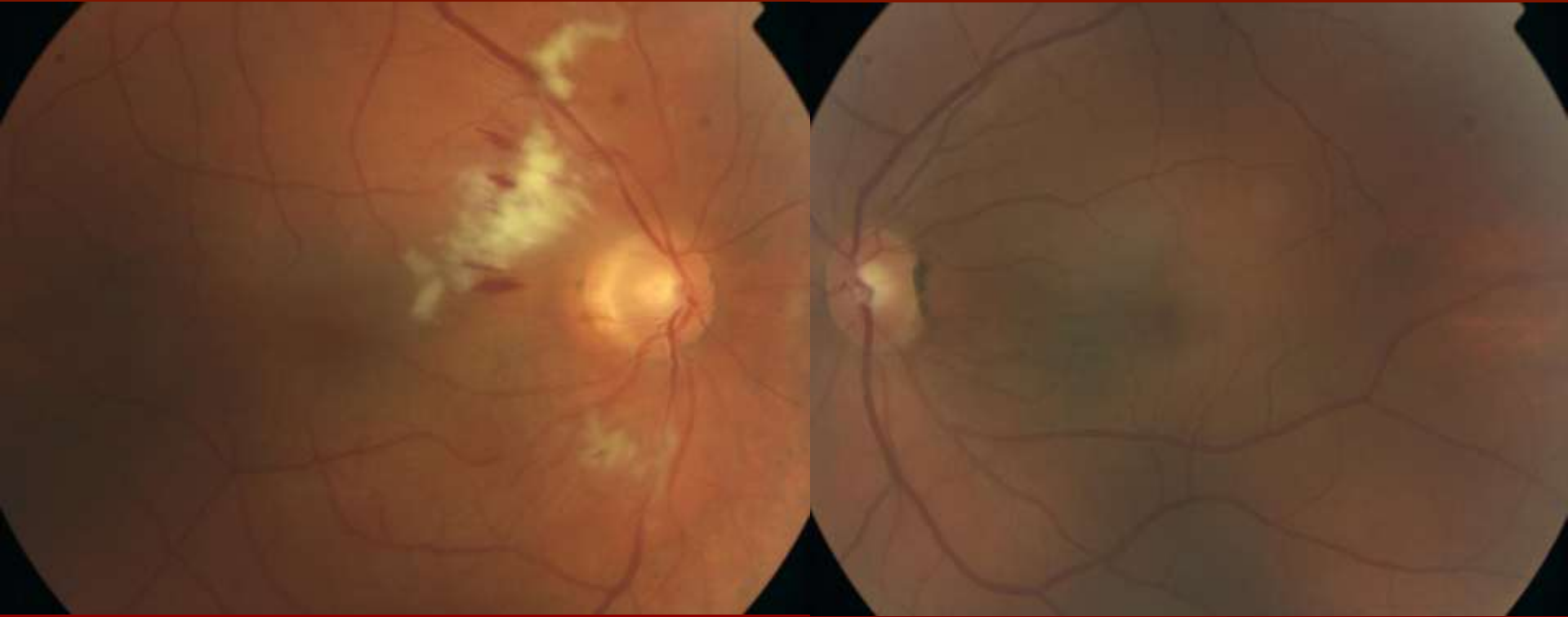
- Gradual change in VA OD, more prominent in the central inferior field.

- PMH:
  - Choroidal melanoma: Dx in 12/2008. Rx with plaque radiotherapy in 1/2009. Last visit in 8/2010 told that tumor is inactive.
- ROS: unremarkable.
- Medications: None
- Allergies: NKDA
- Family Hx: irrelevant
- Social Hx: Nurse, no alcohol or drugs

# Examination:

- Visual acuity OD: 20/30, OS:20/20.
- IOP:
  - OD: 10 mmHg
  - OS: 13 mmHg
- Anterior segment exam otherwise was unremarkable.

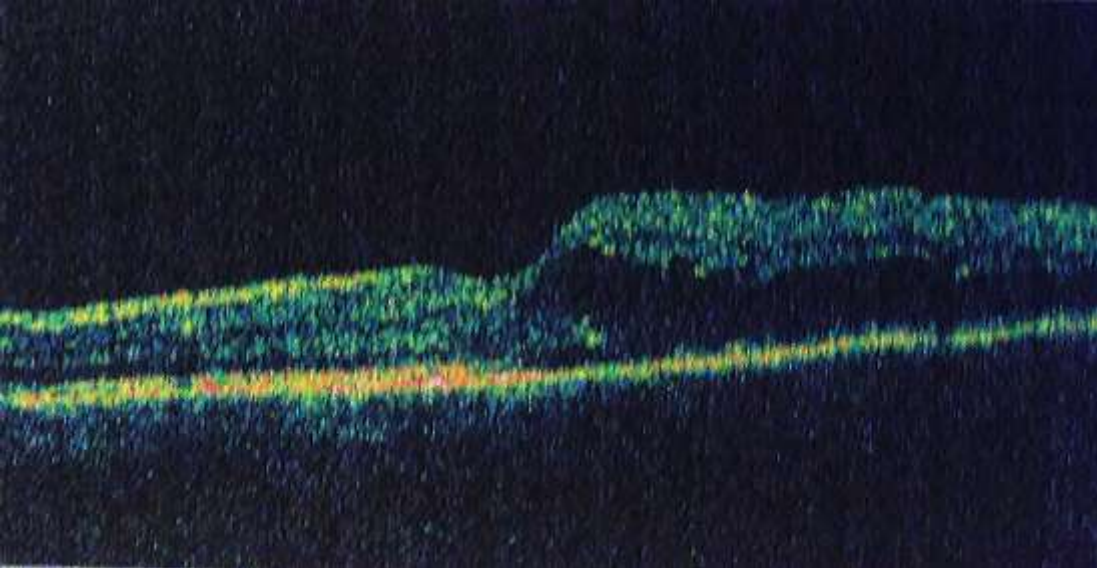
# Fundus Exam:



OD: Cotton-wool spots (CWS), intraretinal heme,  
(macular edema).

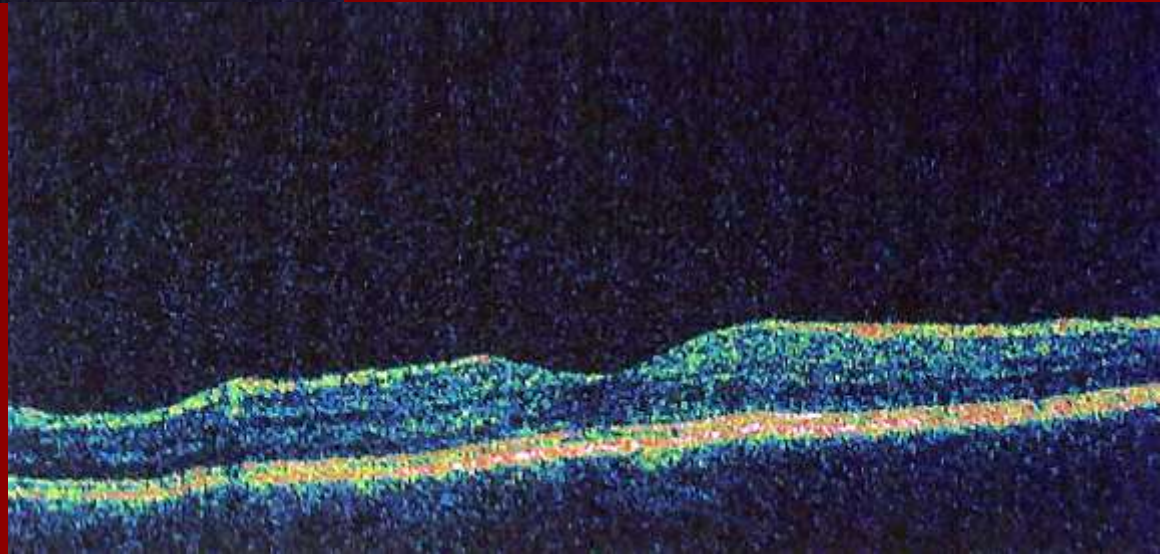
OS: WNL

# *OCT*

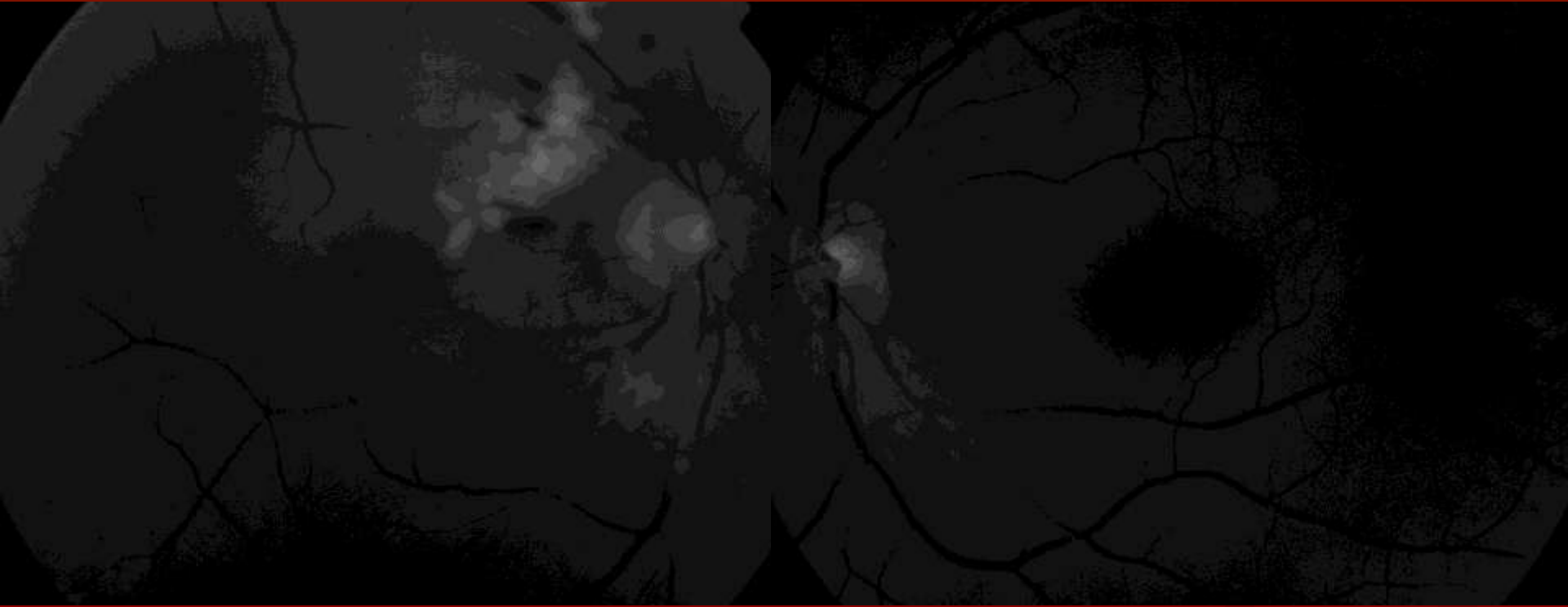


OD:  
Retinal edema, small  
subretinal cyst, loss of  
photoreceptors.

OS: WNL



# FFA: Red free




- CWS, Retinal hemorrhages OD

# FFA: OD



Areas of hypofluorescence corresponding to CWS and retinal heme. Multiple focal areas of leakage involving the fovea. Areas of capillary nonperfusion.

# FFA: OD



Late leakage involving the fovea, staining of the venous walls

**FFA: OS**



**OS: WNL**

# Impression:

- 33 y old female with radiation retinopathy secondary to plaque radiotherapy for choroidal melanoma.

# Plan:

- Intravitreal bevacizumab OD.

# Radiation retinopathy

- Radiation retinopathy (RR) was first described by Stallard in 1933.
- Can result from radiation therapy to ocular or extraocular tissues.
- A major cause of vision loss after radiotherapy.
- Incidence of RR is 10-63%.

# Mechanism:

- Direct interaction of radiation with DNA, which results in DNA breaks and impaired cell function.
- Indirect DNA damage by radiation-induced free radicals.

# Pathophysiology

- Main cell that is affected is the endothelial cells.
- Endothelial cell death leads eventually to obliteration of the blood vessels and ischemia.

# Risk factors

- Total dose of radiation.
- Proximity of the plaque to the affected tissues.
- Presence of systemic vascular diseases such as diabetes and hypertension.

# Clinical features:

- Categories:
  - Nonproliferative RR (NPRR): characterized by microaneurysms, retinal hemorrhages, telangiectasia.
  - Proliferative RR (PRR): neovascularizations, vitreous hemorrhage and tractional retinal detachment.
  - Maculopathy: macular edema or ischemic. carries poor visual prognosis.
  - Optic neuropathy
- Mean time of onset is 12 months (range 6mon-3 y)

# Treatment:

- Laser photocoagulation:
  - Standard for PRR.
  - Finger and Kurli reported an interventional case series in 2005 for treatment of RR with laser photocoagulation.
    - 45 eyes with RR treated with laser( mean 2.75 sessions, f/u 48 mo)
    - 16 eyes ( high-risk) without RR were treated also ( mean 1.5 sessions, f/u 16.5 mo).
    - RR regressed in 64.4% of the treated group. 46.7% lost 3 or more lines of vision.
    - Of the high risk group, none developed RR, none lost more than 3 lines of vision.

## ■ Steroids:

- Intravitreal triamcinolone: single case reports and short case series reported benefits in improving or stabilizing the vision and reducing OCT thickness.
  - Shields et al. reported the effect of intravitreal triamcinolone (4 mg/1 mL) in a prospective case series of 31 patients with radiation-induced macular edema.
  - Visual acuity was stable or improved in 91% of patients by one month and 45% by six months.
  - There was also a decrease in the mean central subfield foveal thickness measured by OCT.

Shields CL, Demicri H, Dai V, et al. Retina 2005, 25: 868-874

- Pericocular triamcinolone:
  - Horgan et al. in 2009 published a large RCT that compared pericocular triamcinolone (40mg, 1 ml) to a control group in preventing RR after plaque radiotherapy.
  - 163 total ( 55 control, 108 treatment group).
  - Injections were given at the time of radiotherapy, 4 and 8 months.
  - Reduced rate of radiation-induced macular edema.
  - Reduced rate of severe ( 5 vs 15%) and moderate vision loss(31 vs 48%) over 18 mon followup.

## ■ Anti-VEGF:

- Bevacizumab has been shown to have beneficial effect in small case series and case reports.
  - Finger reported a case series of 21 patients treated with bevacizumab (1.25mg, 0.05ml) for RR.
  - Pts received injection every 6-8 wks, average number of injections 3.8, mean f/u was 7.8 mo (2-18 mo).
  - 86% stabilized or improved vision.
  - 14% gained 2 or more lines.

- Finger and Chin reported another smaller series including 6 patients.
- After intravitreal bevacizumab (1.25 mg, 0.05 ml), 2 patients had vision improvement and 4 stabilized.
- Most of the patients showed regression of the retinal changes and reduction in the macular edema.

Finger PT, Chin K. Arch Ophthalmol. 2007 Jun;125(6):751-6.

- Other modalities:
  - Hyperbaric oxygen
  - PDT
  - Pentoxifylline
- Scott et al. recently suggested the use of vitreous substitutes at the time of radiation to reduce the amount absorbed by the ocular tissues.
- Silicone oil 1000 was found to reduce the signal by 48%.

Scott CN; Min YL, John JD et al. Arch Ophthalmol. 2010;128(7):888-893

# References:

- Zamber RW, Kinyoun JL: Radiation retinopathy. *West J Med* 1992 Nov; 157:530-533
- Giuliari GP, Sadaka A , Hinkle DM, Simpson ER. Current treatments for radiation retinopathy. *Acta Oncologica*, 2010; Early Online, 1–8.
- Horgan N., Shields CL, Mashayekhi A., Shields JA. Classification and treatment of radiation maculopathy. *Curr Opin Ophthalmol* 2010 21:233–238.
- Wen JC, McCannel TA. Treatment of radiation retinopathy following plaque brachytherapy for choroidal melanoma. *Curr Opin Ophthalmol*. 2009 May;20(3):200-4.
- Finger PT, Kurli M. Laser photocoagulation for radiation retinopathy after ophthalmic plaque radiation therapy. *Br J Ophthalmol* 2005; 89: 730-738.
- Shields CL, Demicri H, Dai V, et al. Intravitreal triamcinolone acetate for radiation maculopathy after plaque radiotherapy for choroidal melanoma. *Retina* 2005, 25: 868-874
- Horgan N, Shields CL, Mashayekhi A, et al. Periocular triamcinolone for prevention of macular edema after iodine 125 radiotherapy of uveal melanoma. *Retina* 2008; 28: 987-995.
- Horgan N, Shields CL, Mashayekhi A, Salazar PF, Materin, MA, O'Regan M, et al. Periocular Triamcinolone for Prevention of Macular Edema after Plaque Radiotherapy of Uveal Melanoma: A Randomized Controlled Trial *Ophthalmology*, Volume 116, Issue 7, July 2009, Pages 1383-1390
- Finger PT. Radiation retinopathy is treatable with antivascular endothelial growth factor bevacizumab (Avastin). *Int J Radiat Oncol Biol Phys* 2008; 70:974-977.
- Finger PT, Chin K. Anti-vascular endothelial growth factor bevacizumab (avastin) for radiation retinopathy. *Arch Ophthalmol*. 2007 Jun;125(6):751-6.
- Scott CN; Min YL, John JD et al. Attenuation of Iodine 125 Radiation With Vitreous Substitutes in the Treatment of Uveal Melanoma *Arch Ophthalmol*. 2010;128(7):888-893

**Thank You!**