

Grand Rounds



John C. Randolph MD

University of Louisville School of Medicine

Department of Ophthalmology & Visual Sciences

9/17/10

Subjective

- CC/HPI: 64 year old WM referred from retina service for evaluation of corneal opacities OU. Pt denies any acute visual changes, eye pain, redness or other ocular symptoms
- PMH: DMT2, HTN, hyperlipidemia, Lymphoma s/p chemotherapy and radiation to head and orbit 2004 → remission for 3 years
- POHx: Radiation retinopathy OD - s/p Avastin X 2 OD; CE with PCIOL OD

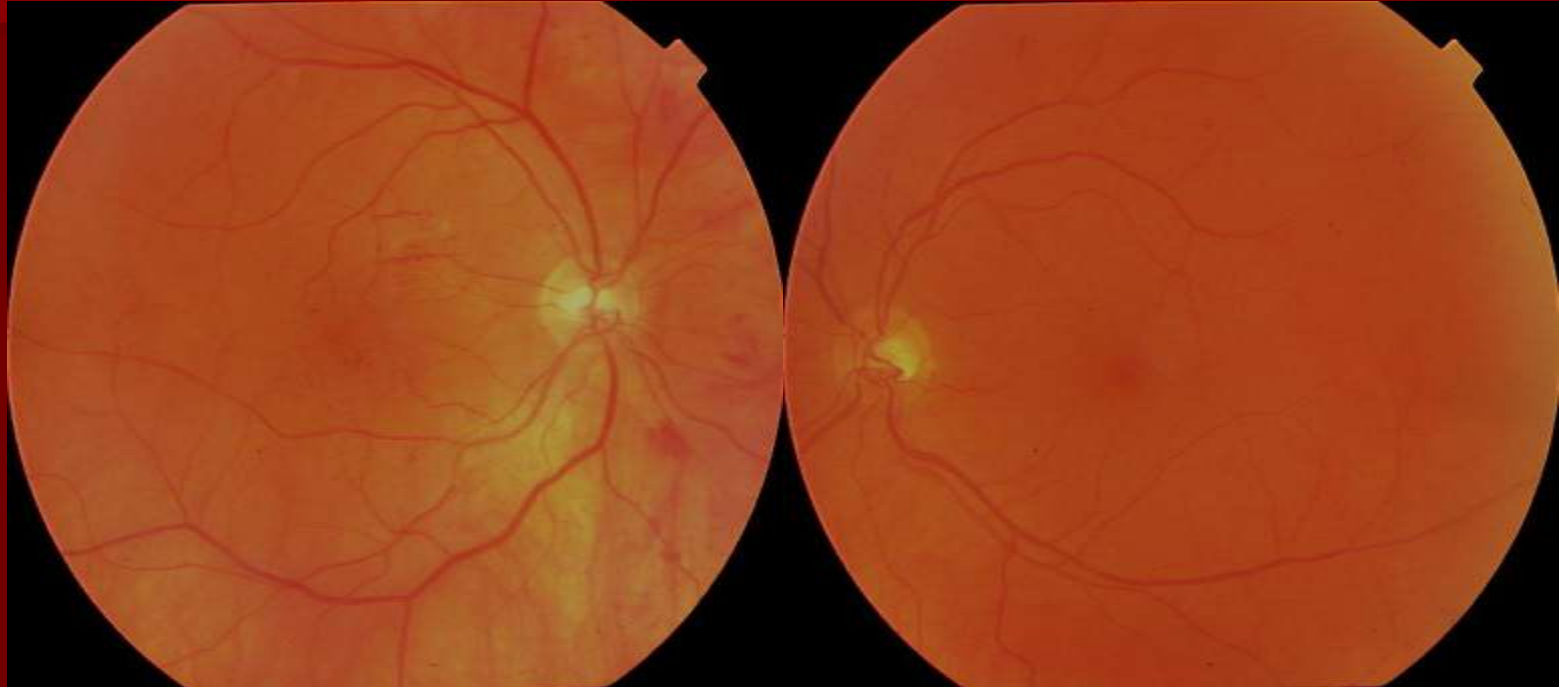Subjective

- Medications: Metformin, glipizide, ASA, HCTZ, lisinopril, atenolol, Lovastatin
- ROS: Denies recent weight loss, fatigue, illness or any changes in overall health. Has not seen oncologist in 2 years (remission)-recent blood work normal

Objective

	OD	OS
<u>Va(Cc):</u>	20/40	20/25
<u>Pupils:</u>	RR no RAPD	
<u>DFE:</u>	Radiation retinopathy OD; macular edema OD	

Color Fundus Photos



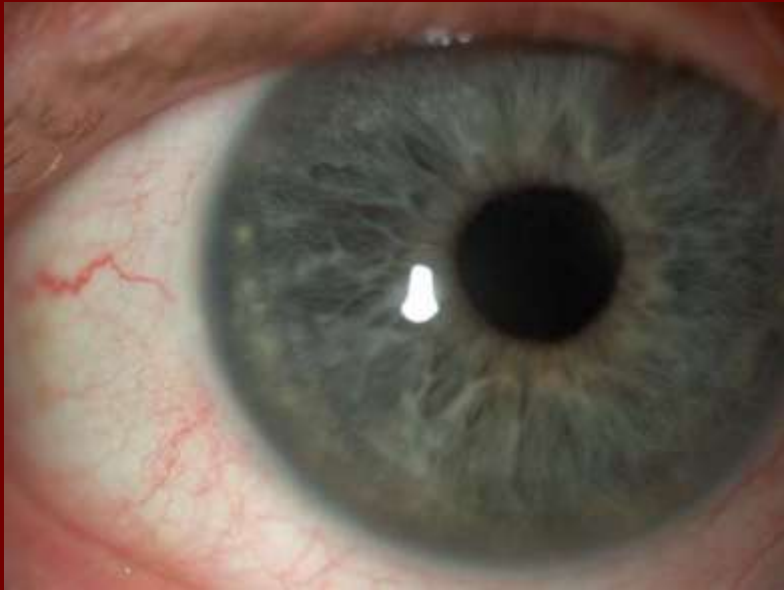- Microaneurysms, pre-retinal and intra-retinal hemorrhages OD with areas of RPE alteration and atrophy. Macular edema OD. OS unremarkable

Objective

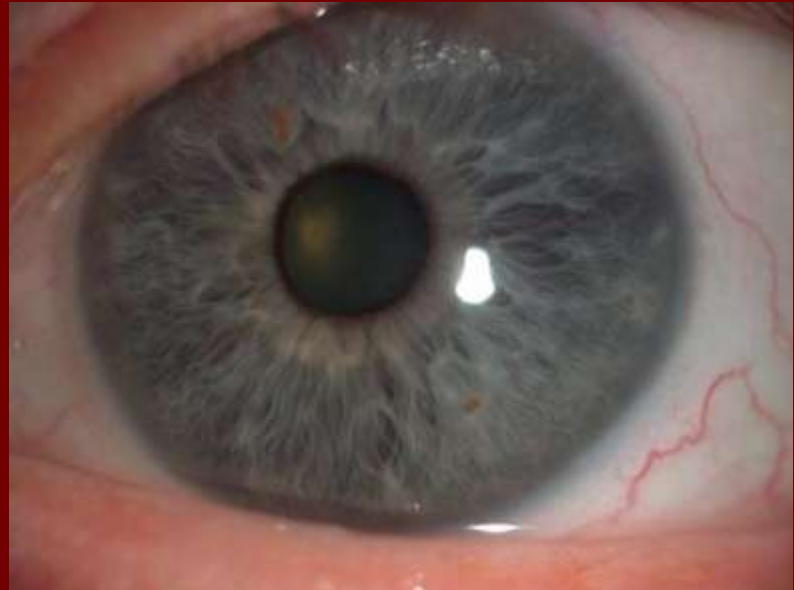Ant Seg:

- Slight epithelial haze
- Diffuse stromal haze
- Discrete stromal opacities
- No cell/flare
- PCIOL OD, NS OS

Color Photos

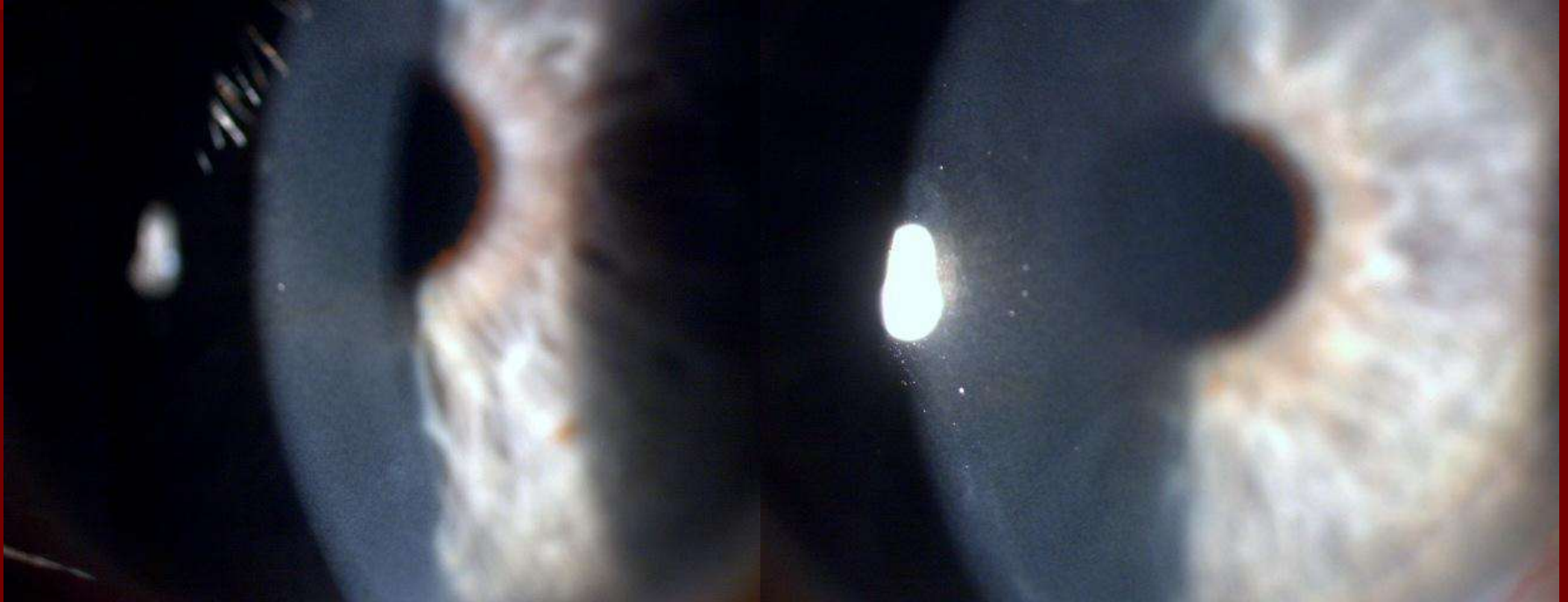

OD



OS

Slit Lamp photos OD



Slight Epithelial haze; Diffuse stromal haze; Normal endothelium

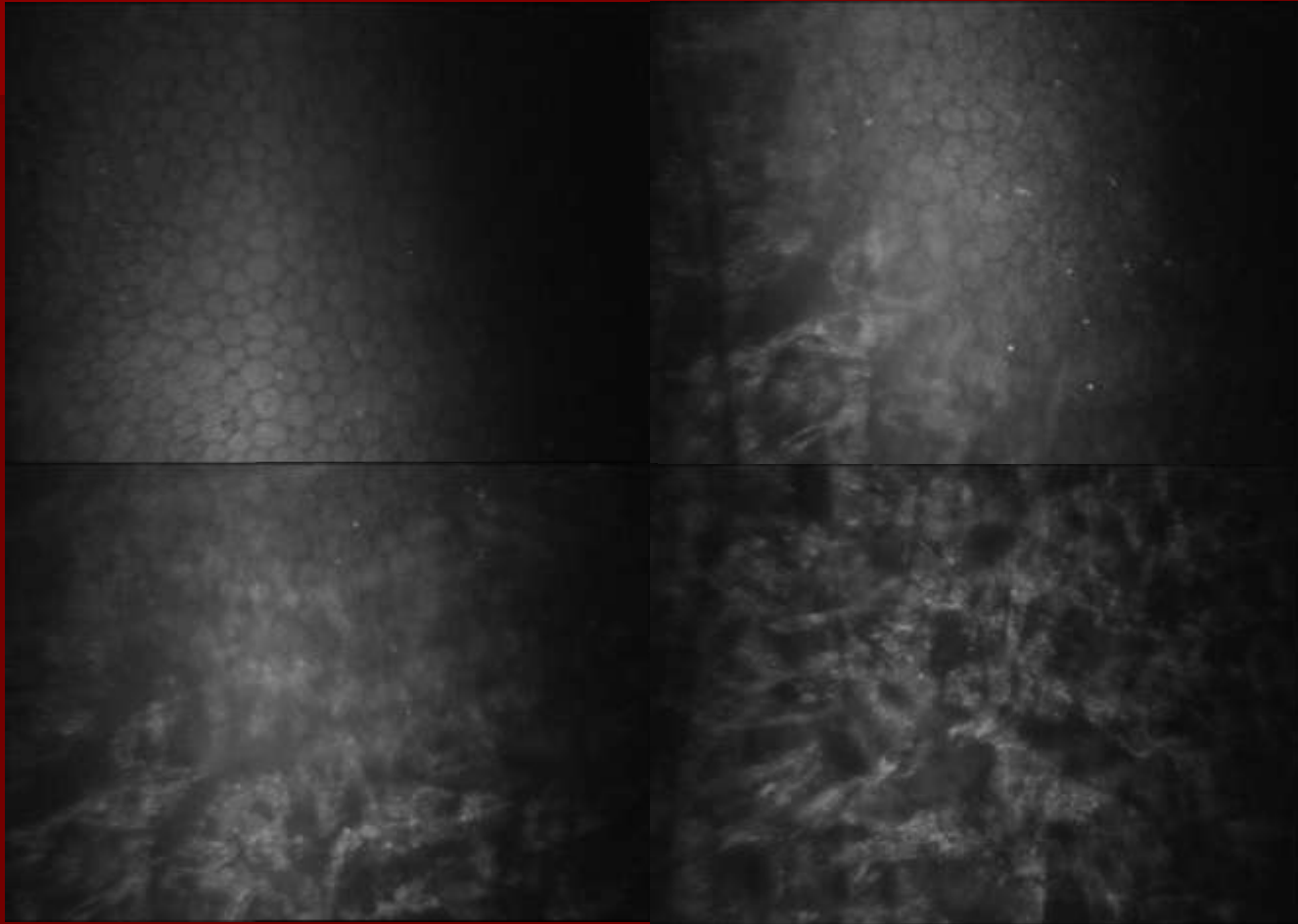
Assessment

- 64 yo WM with history of orbital lymphoma s/p chemo/radiation
- Diffuse epithelial/superficial stromal haze
OU

Plan

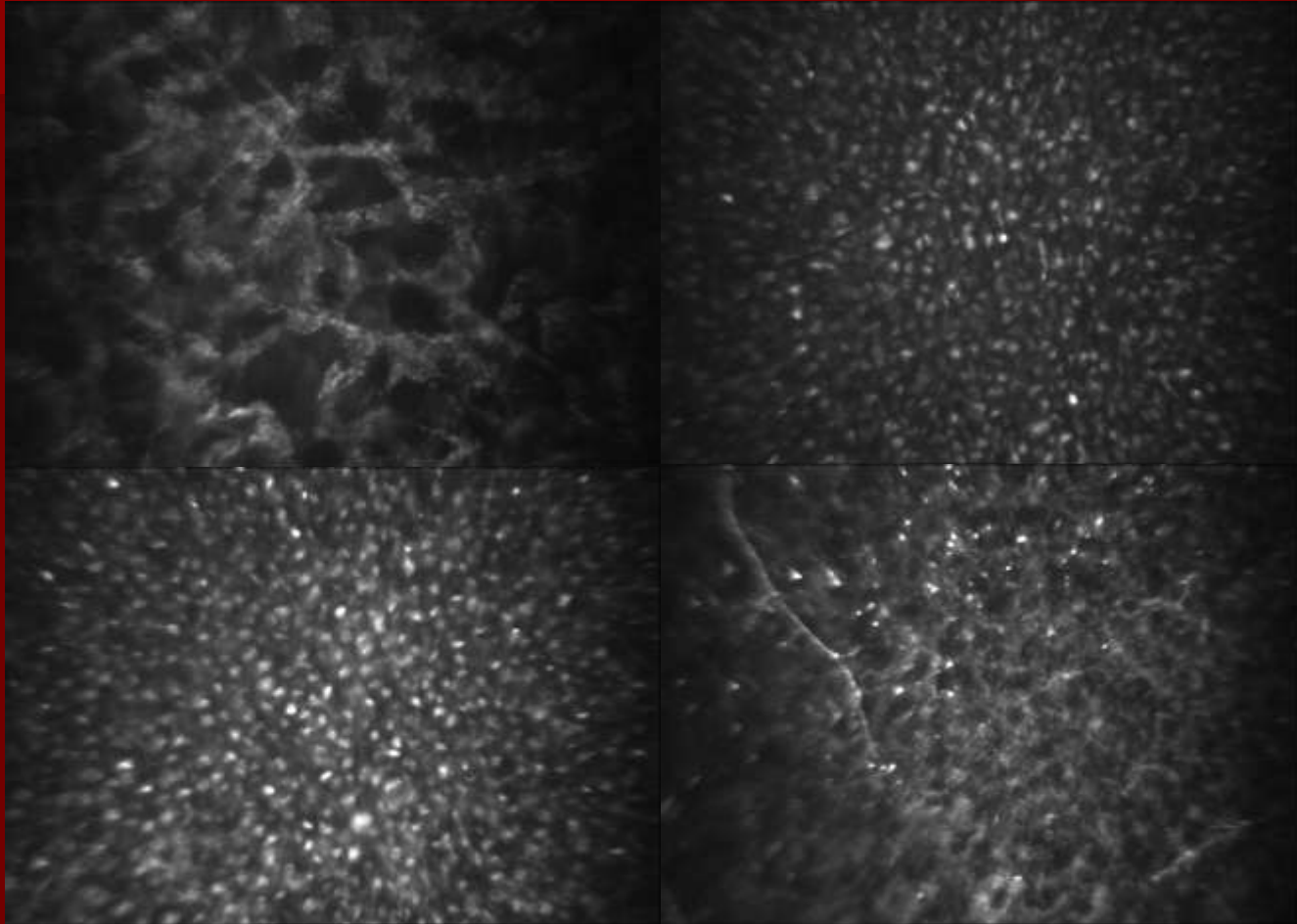
- Confocal microscopy

Confocal



- Normal endothelium and deep stromal layers

Confocal



- Hyper-reflective deposits in the superficial stromal layers and subepithelial layers

Assessment

- 64 yo WM with history of orbital lymphoma s/p chemo/radiation
- Diffuse stromal/epithelial haze OU and hyper-reflective deposits on confocal microscopy

- Differential Diagnosis?
- Course of Action?

Differential Diagnosis

- Crystalline keratopathy
 - Lymphoproliferative (Monoclonal gammopathy)
 - Infectious
 - Dystrophies (Schnyder, Bietti)
 - Metabolic (Uric acid, Cystinosis)
 - Medication induced (topical fluoroquinolone drops)

Course

- Serum protein electrophoresis (SPEP)

Course-Lab results

- IgG – 1870 mg/dl*
- IgA – 34 mg/dl
- IgM – 16.9 mg/dl
- Kappa light chains – 2280 mg/dl *
- Alpha light chains – 15.2 mg/dl
- Lambda light chains – 80 mg/dl

- Monoclonal gammopathy

Course

- Patient referred back to oncologist for further workup

Course

- Oncologist confirmed stage 1 multiple myeloma via bone marrow aspiration
- Treatment was deferred by oncologist
- Patient has remained stable

Discussion

- Multiple myeloma associated crystalline keratopathy was first described in 1958 by Burki and is a rare condition.
- Corneal crystals are seen in < 1% of the patients with a monoclonal gammopathy.
- The rarity of such corneal changes is related to two factors:
 - A gammopathy of IgG kappa light chain must be present
 - The disease must be chronic.
 - Our patient: IgG – 1870 mg/dl*; Kappa light chains – 2280 mg/dl *; had not seen his oncologist for 2 years.

Discussion

- The precise etiology of corneal immunoglobulin deposition is not known.
 - spontaneous crystallization
 - phagocytosis by keratocytes
 - supply of crystals by the limbal vessels.

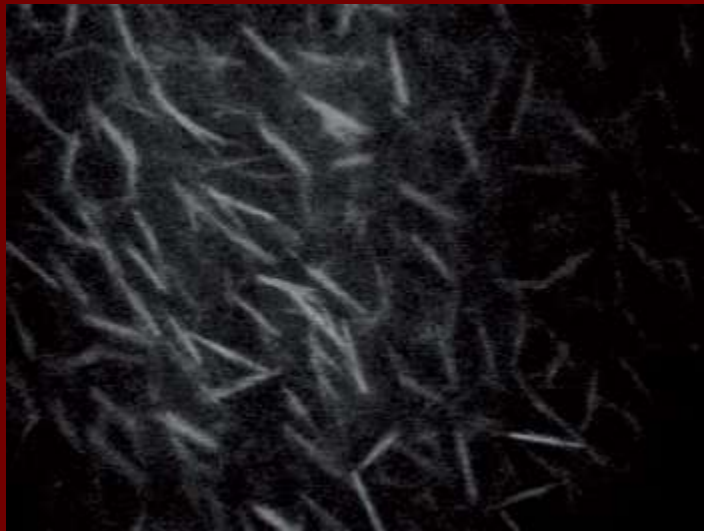Discussion



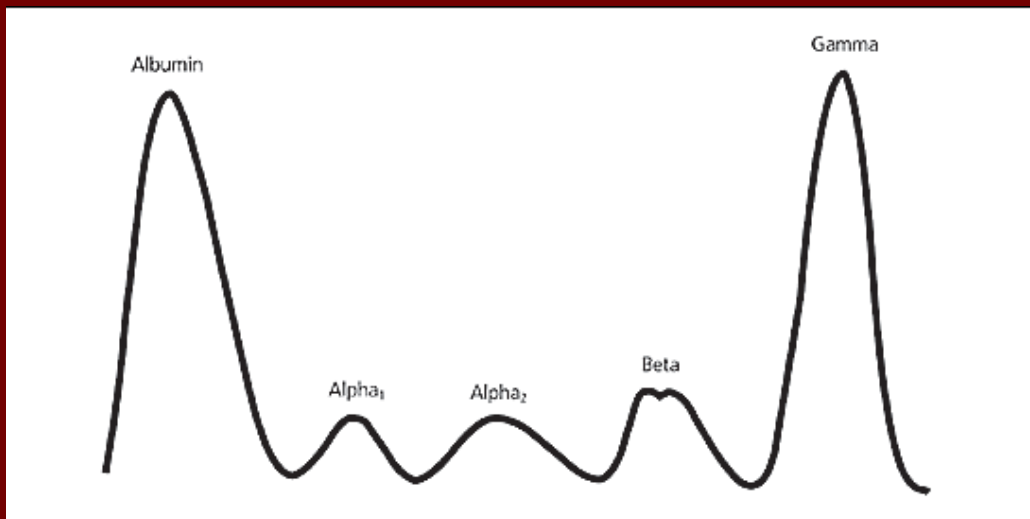
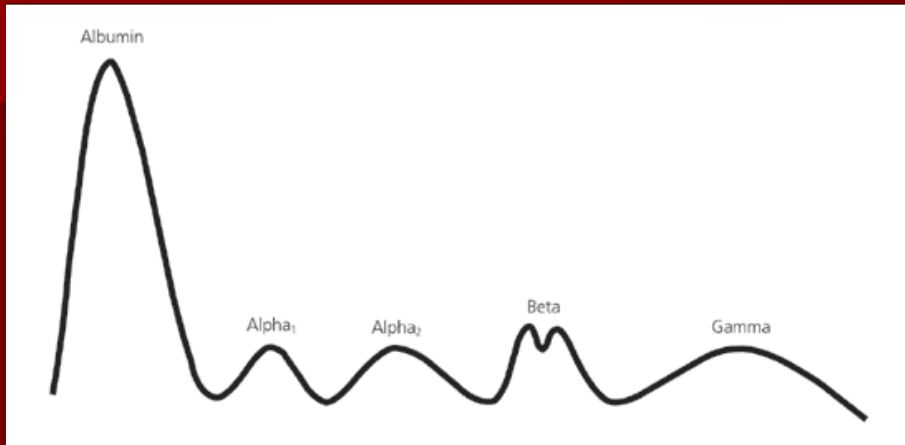
- Peripheral corneal biopsies and electron microscopic studies demonstrated that the crystals were located solely within the cytoplasm of keratocytes
- Histochemical studies of the corneal crystals confirmed immunoglobulin crystals
- Serum protein analysis showed that both patients had a monoclonal gammopathy with an elevated IgG level and increased *k* light chains.

Discussion

- These crystals can have numerous morphologies.
 - stick-like structures with rounded edges
 - irregularly arranged
- Histopathologic examination
 - Rectangular or rhomboidal
 - They have also been described as trapezoidal, pentagonal and hexagonal.
 - Commonly in superficial stroma and epithelial layers



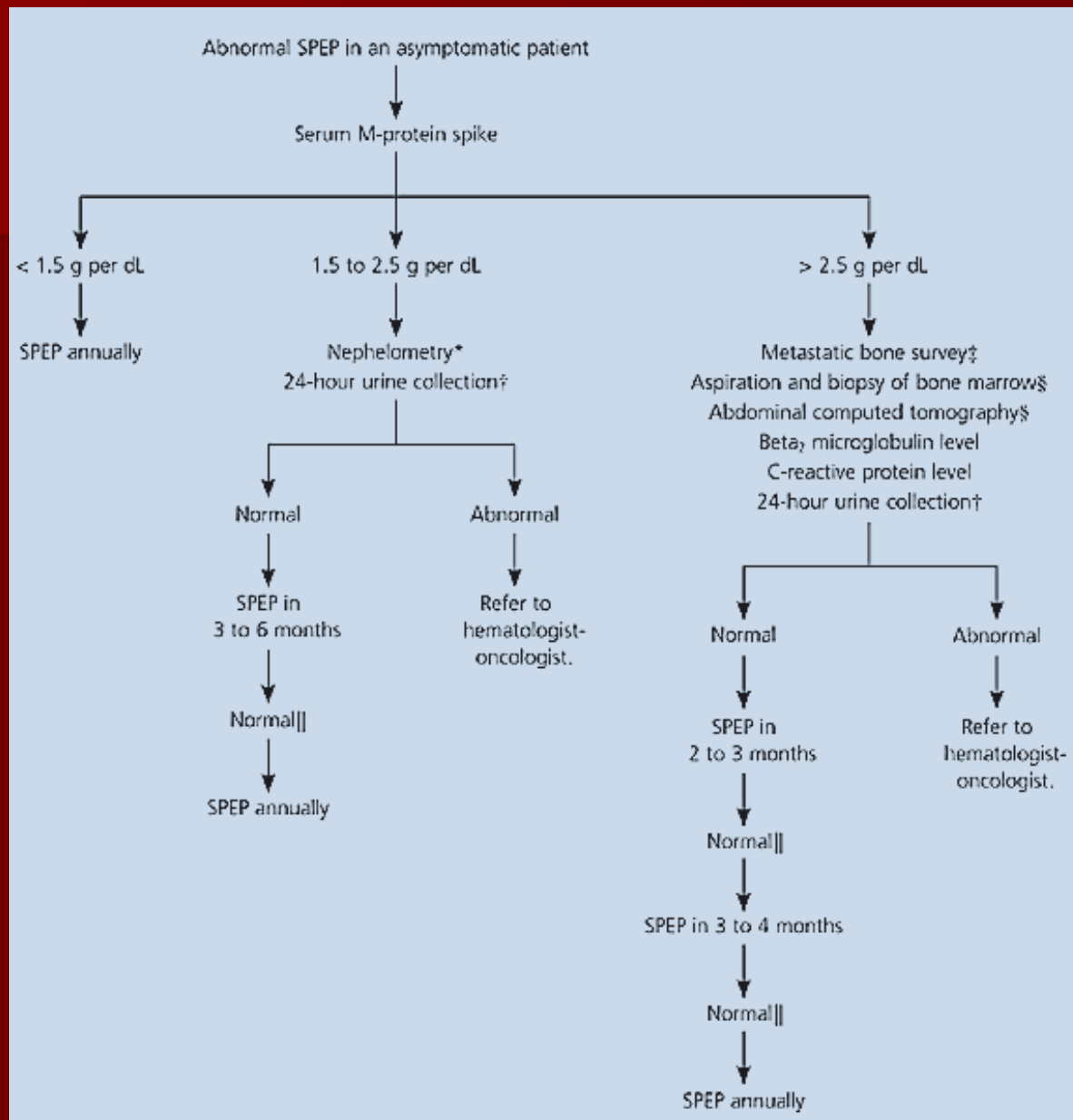
SPEP



- The alpha fraction is comprised of alpha1-antitrypsin, thyroid-binding globulin, and transcortin
- Beta is composed mostly of transferrin, and beta-lipoprotein
- The Gamma protein fraction: IgA, IgM, and sometimes IgG

SPEP

- A homogeneous spike-like peak in a focal region of the gamma-globulin zone indicates a monoclonal gammopathy.
- Associated with a clonal process that is malignant or potentially malignant:
 - Multiple myeloma
 - Waldenström's macroglobulinemia
 - solitary plasmacytoma
 - smoldering multiple myeloma
 - monoclonal gammopathy of undetermined significance
 - plasma cell leukemia
 - heavy chain disease
 - amyloidosis

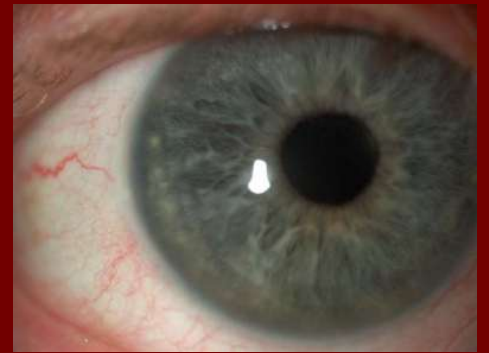
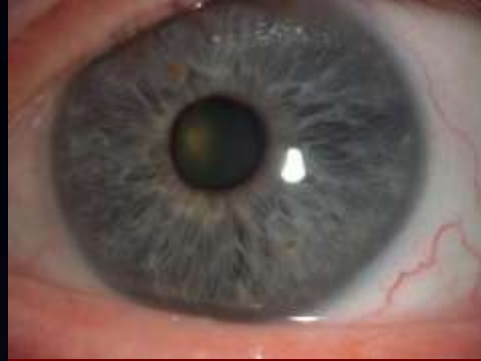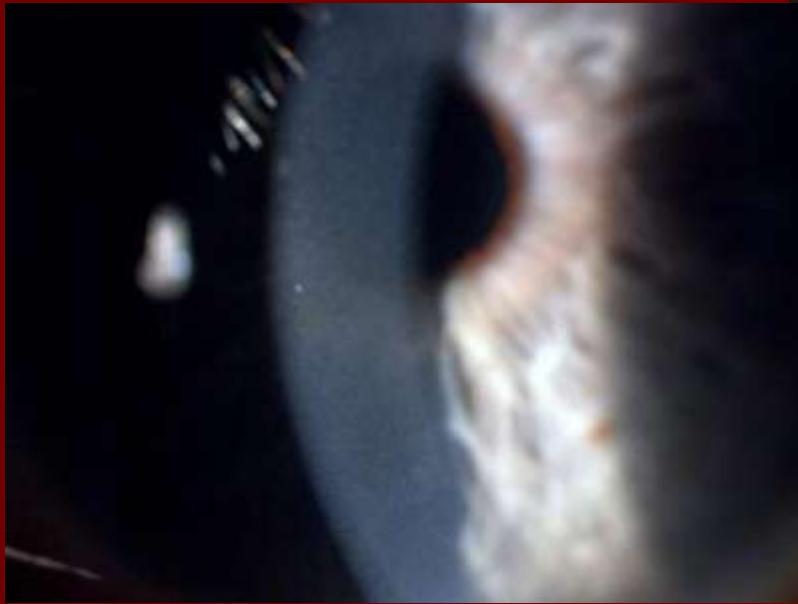
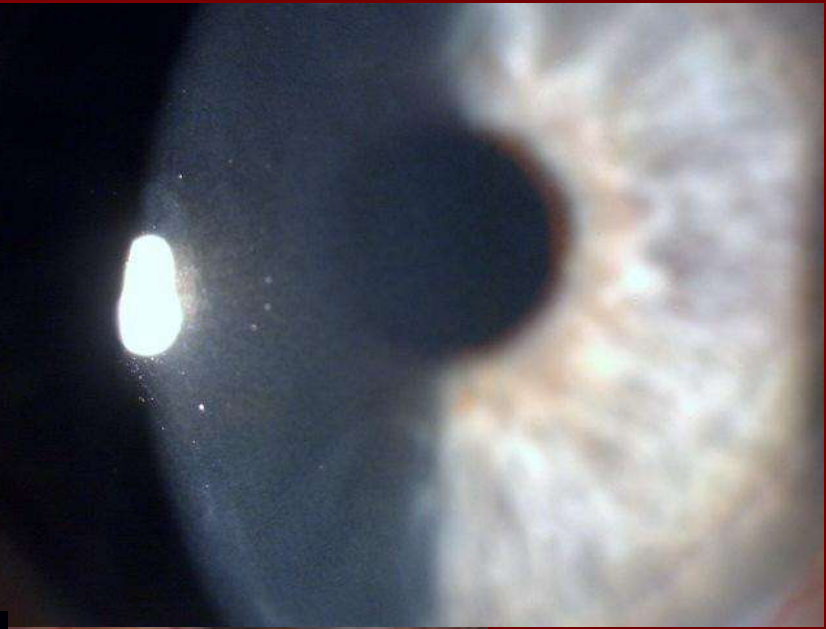
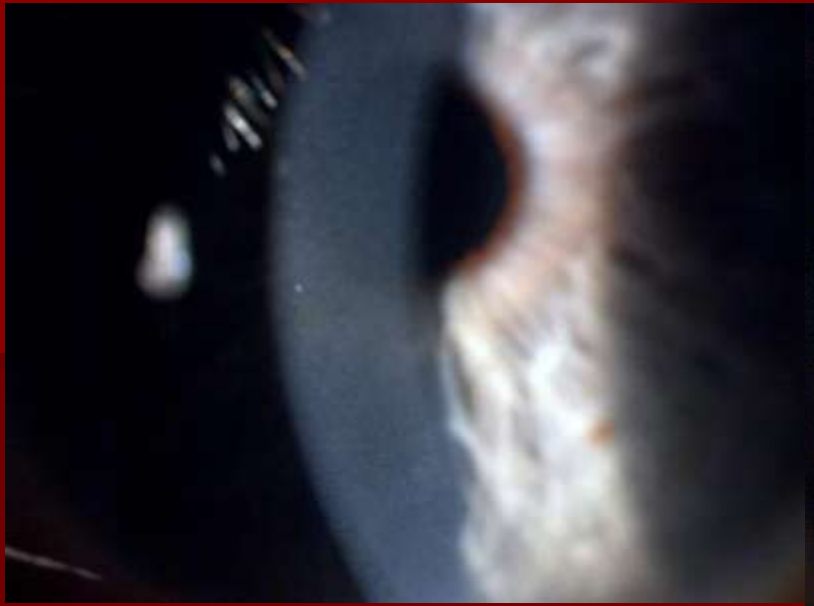


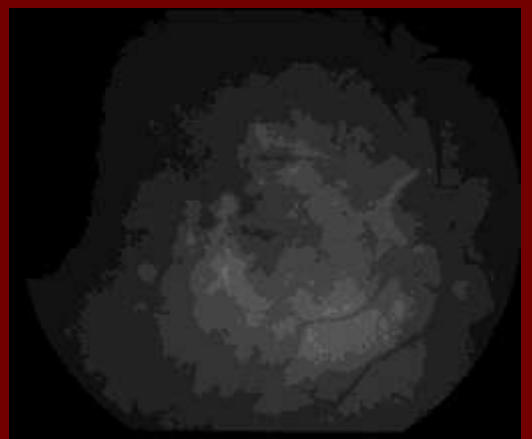
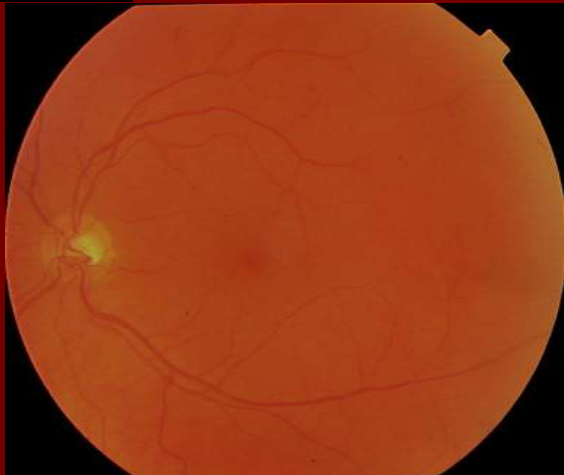
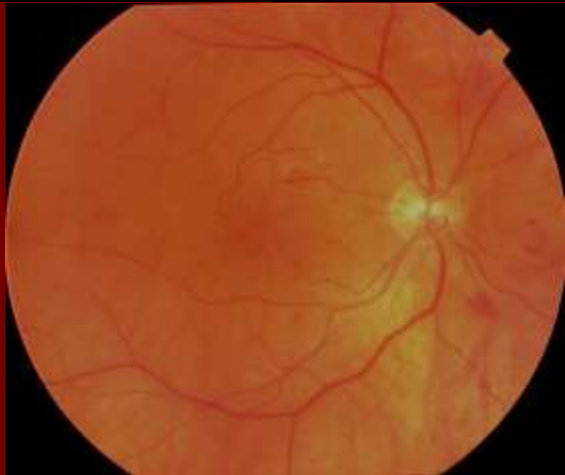
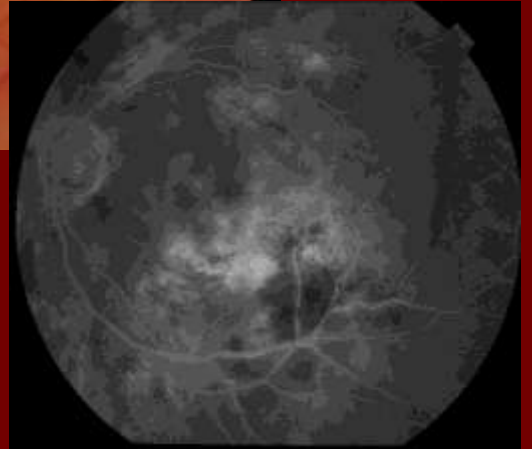
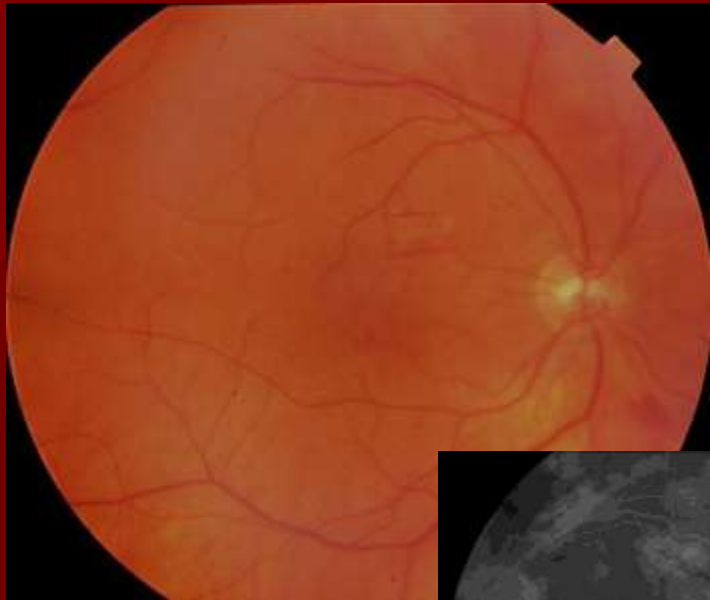
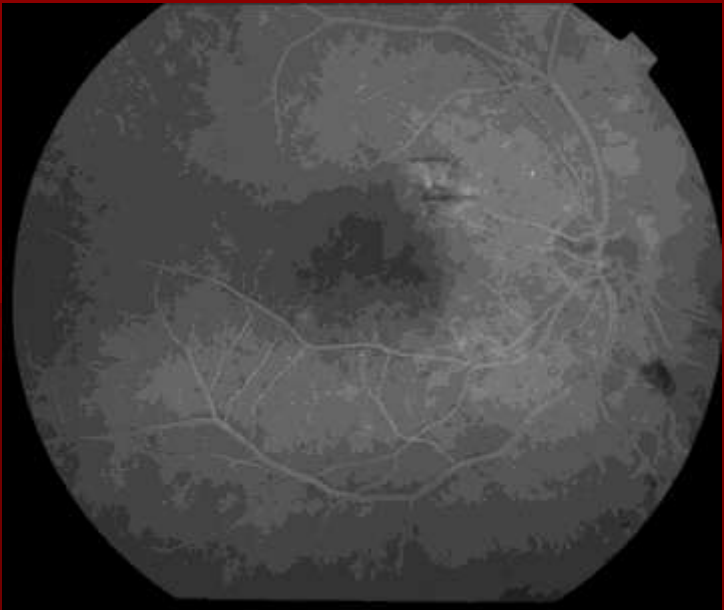
Conclusion

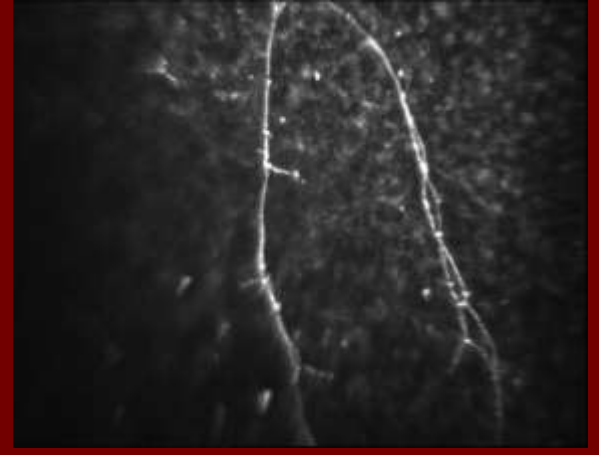
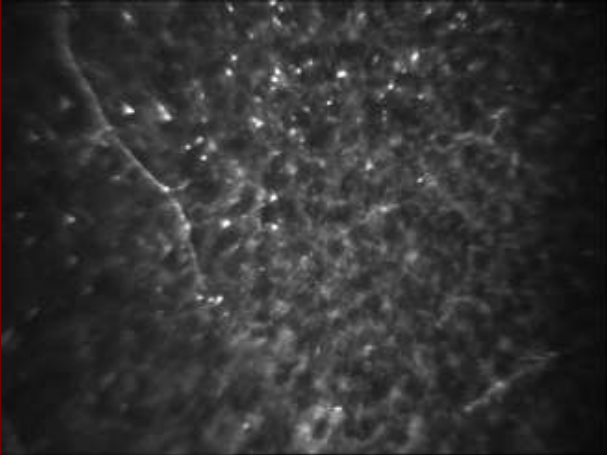


- Crystalline keratopathy encompasses a broad category of disease processes
- Corneal involvement in monoclonal gammopathies is rare (<1%)
- Suspicion for malignancy → confocal microscopy, SPEP and prompt referral to PCP/oncologist for further evaluation

References

- BARR C.C., GELENDER H., FONT R.L. – Corneal crystalline deposits associated with dysproteinemia. *Arch Ophthalmol* 1980; 98: 884- 889.
- BOURNE W.M., KYLE R.A., BRUBAKER R.F., GREIPP P.R. – Incidence of corneal crystals in the monoclonal gammopathies. *Am J Ophthalmol* 1989; 107: 192-193.
- BUERK B.C., TU E. – Confocal microscopy in multiple myeloma crystalline keratopathy. *Cornea* 2002; 21: 619-620.
- BURKI E. – Über Hornhautveränderungen bei einem Fall von multiplem yelom(Plasmocytom). *Ophthalmologica* 1958; 135: 565-572.
- CHERRY P.M.H., KRAFT S., MCGOWAN H., GHOSH M., SHENKEN E. – Corneal and conjunctival deposits in monoclonal gammopathy. *Can J Ophthalmol* 1983; 18: 142-149.
- CHONG E., CAMPBELL R.J., BOURNE W.M. – Vortex keratopathy in a patient with multiple myeloma. *Cornea* 1997; 16: 592-594.
- GARIBALDI D.C., GOTTSCH J., DE LA CRUZ Z., HAAS M., GREEN W.R. – Immunotactoid keratopathy: a clinicopathologic case report and a review of reports of corneal involvement in systemic paraproteinemias. *Surv Ophthalmol* 2005; 50: 61-80.
- HURLEY I.W.J., BROOKS A.M.V., REINEHR D.P., GRANT G.B., GILLIES W.E. – Identifying 16 anterior segment crystals. *Br J Ophthalmol* 1991; 75: 329-331.
- KLINTWORTH G.K., BREDEHOEFT S.J., REED J.W. – Analysis of corneal crystalline deposits in multiple myeloma. *Am J Ophthalmol* 1978; 86: 303-313.
- MILLER K.H., GREEN W.R., STARK W.J., WELLS H.A., MENDELSON G., KANHOFER H. – Immunoprotein deposition in the cornea. *Ophthalmology* 1980; 87: 944-950.
- PERRY H.D., DONNENFELD E.D., FONT R.L. – Intraepithelial corneal immunoglobulin crystals in IgG-Kappa multiple myeloma. *Cornea* 1993; 12: 448-450.
- RODRIGUES M.M., KRACHMER J.H., MILLER S.D., NEWSOME D.A. – Posterior corneal crystalline deposits in benign monoclonal gammopathy: a clinicopathologic case report. *Arch Ophthalmol* 1979; 97: 124-128.









k you